



**PATIENT**

Carter Rescue Outreach

**SPECIES**

Feline

**BREED**

DMH

**SEX**

Male

**AGE**

8 weeks

**WEIGHT**

2lbs

**INTERPRETED BY**

Maggie Machen Lamy, DVM, DACVIM (Cardiology)

**IMAGING PERFORMED BY**

Sarah Pender, CVT

**HOSPITAL NAME**

SVS Imaging QC

**REFERRING VET**

Rescue Outreach

**INVOICE**

27029

**DATE**

10/20/22

**PRESENTING CLINICAL SIGNS**

History: Last Friday went to ER for coughing, more labored breathing, and sounded like rattling with breaths. Acting normal otherwise E/D ok, playing as usual. Since starting Furosemide seems better. -Radiographs (at ER): pleural effusion.

**ECHOCARDIOGRAM FINDINGS**

2D, m-mode, color flow and doppler imaging is available. The left ventricular wall is normal in dimension. No significant LV dilation with adequate function. The papillary muscles are prominent. The left atrium is normal in size. The right atrium is normal in size. The right ventricle appears normal. The mitral valve is normal in structure and mobility. Blood flow through both the LVOT and RVOT is normal in velocity. Trace TR. No pleural or pericardial effusion seen. No obvious cardiac tumors.

**CARDIAC CHART**

FELINE CARDIAC PARAMETERS	BODY WEIGHT (kg)	HR (BPM)	IVSd (cm) (Moise, Pipers)	LVIDd (cm) (Moise, Pipers)	LVWd (cm) (Moise, Pipers)	FS (%)	EF (%)
NORMAL PARAMETER	-----	150-240	0.35-0.55	<2 (mean 1.5)	3.5-0.55	35-67	80-100
PATIENT	0.9	270	0.36	1.2	0.36	63	94
FELINE CARDIAC PARAMETERS	LA/AO (Boon)	LA/AO HEART BASE (Swe) (Abbott)	LA 2D short axis Base view (cm) (Abbott)	LVOT VEL (m/s)	RVOT VEL (m/s)	E max (m/s)	
NORMAL	<1.5	<1.3	<1.2	<1.6	<1.3	<0.9	
PATIENT	NM	1.1	0.7	0.6	1.0	NM	

*\*Note: All measurements based upon multi-modal images and methods. An average value is reported.*  
Adapted from June Boon, Veterinary Echocardiography, 1998  
Abbott J & MacLean H JVIM 2006;20: 111-119, Moise et al. Am J Vet Res 47:1476, 1986. Pipers et al. Am J Vet Res 40:882, 1979.

**INTERPRETATION OF THE FINDINGS & FURTHER RECOMMENDATIONS**

Overtly normal cardiac structure and function without obvious structural disease. The LV wall thickness is normal and there is no evidence of elevated left atrial pressure. No obvious congenital shunts or defects are visualized; however, it is important to note that small abnormalities are easily missed particularly in juvenile kittens. The patient is highly tachycardic and difficult to evaluation, and advanced imaging should be considered.

Given these findings, there is no obvious structural cause for pleural effusion and CHF in an 8 week old kitten is highly unlikely. If leural effusion is confirmed, other possibilities should be considered. Recommend sampling, advanced thoracic imaging, etc. Referral is advised. No medications are indicated at this time and Lasix can be discontinued.

No cardiac contraindication for general anesthesia.

Recommend recheck echocardiogram should a murmur, gallop or clinical signs of cardiac compromise be noted in the future.

**IMAGING PERFORMED BY**

svsmobileimaging.com 309 - 737 - 3070



**Clinical Sonography & Telectology**

EDUCATIONAL TELECONSULTATION SERVICES™

1-800-838-4268 info@sonopath.com SonoPath.com

**PATIENT**

Carter Rescue Outreach

**SPECIES**

Feline

**BREED**

DMH

**SEX**

Male

**AGE**

8 weeks

**WEIGHT**

2lbs

**INTERPRETED BY**

Maggie Machen Lamy, DVM, DACVIM (Cardiology)

**IMAGING PERFORMED BY**

Sarah Pender, CVT

**HOSPITAL NAME**

SVS Imaging QC

**REFERRING VET**

Rescue Outreach

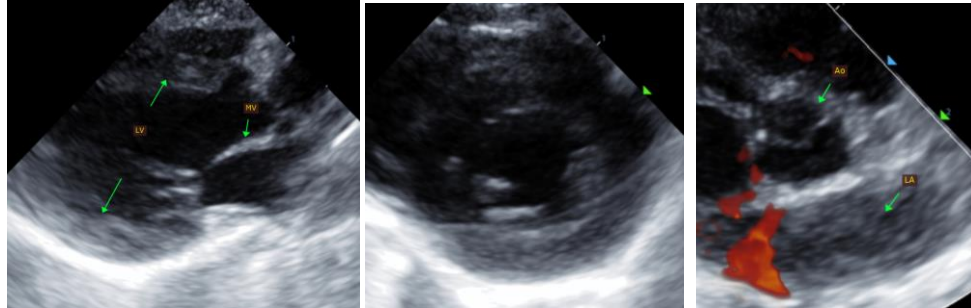
**INVOICE**

27029

**DATE**

10/20/22

**IMAGES**



The information and recommendations provided are based on the images presented by the referring veterinarian. No evaluation can be communicated regarding pathology that was not visible in the image/video clips provided.

Thank you for this referral. If the clinical or image interpretation does not parallel your findings or if I can be of any further assistance, please contact me.

Maggie Machen Lamy, DVM  
Diplomate of the American College of Veterinary Internal Medicine (Cardiology)  
info@sonopath.com